



¹ Department of Internal Medicine, Christian Medical College, Vellore, Tamil Nadu, 632004, India

² Dev Care Foundation, Dhaka-1209, Bangladesh

³ Department of Internal Medicine, B.P. Koirala Institute of Health Sciences, Dharan, 76500, Nepal

⁴ Dynamic Portfolio, Drugs for Neglected Diseases (DND), 15 Chemin Louis-Dunant, 1202, Geneva, Switzerland

⁵ Division of Tropical and Humanitarian Medicine, Geneva University Hospitals, Rue Gabrielle-Perret-Gentil 6, Geneva, CH 1211, Switzerland

Correspondence to: R Ralph ravikar_ralph@yahoo.com

Cite this as: *BMJ* 2022;376:e057926

<http://dx.doi.org/10.1136/bmj-2020-057926>

Published: 07 January 2022

CLINICAL UPDATE

Managing snakebite

Ravikar Ralph,¹ Mohammad Abul Faiz,² Sanjib Kumar Sharma,³ Isabela Ribeiro,⁴ François Chappuis⁵

What you need to know

- Bites from venomous snakes can result in bleeding, paralysis, long term disability, and death
- Immobilise the bitten limb when transporting the patient to a medical facility; the universal use of pressure immobilisation is controversial, and tourniquets are not recommended
- The 20-minute whole blood clotting test is a simple bedside test to screen for and monitor coagulopathy in resource-limited settings
- Assess vital parameters and initiate resuscitation measures if the patient is clinically unstable with signs of bleeding, shock, paralysis, or respiratory distress
- Intravenous antivenom is recommended in patients with systemic symptoms; the dose and type depend on likely snake species, local guidelines, and availability

Sources and selection criteria

We searched the Cochrane Library, Google, and PubMed, using the MeSH terms: “(snakebite, diagnosis and treatment guidelines) and (snake, scientific names of individual snake species, snakebite, envenoming, venom, and antivenom)”. Research papers and case reports from Latin America, South and South-East Asia, and sub-Saharan Africa were retrieved. There were no language restrictions. Additional articles were obtained by citation tracking of review and original articles. Although the search focused on key papers published in the past five years, older publications of importance have been included. The review also drew from the widely established African and South-East Asian regional guidelines on the treatment and prevention of snakebite envenoming.

Who is at risk of snakebite?

Rural communities in tropical countries are worst affected.¹³⁻¹⁶ Agricultural workers, hunter-gatherers, herders, fishermen, and rural families living in precarious housing conditions with outdoor toilets have a higher risk of snakebite. Their living environments intersect with snake habitats.¹² Men between 10 and 40 years are more commonly affected.^{4 15 17-20} Non-mechanised farming techniques, barefoot farming, and sleeping on the floor further increase the risk.^{16 21} Bites are more common during wetter months, when agricultural activities and breeding season for snakes potentially converge.^{15 17 20 22 23}

How does envenoming occur?

Most medically important snakes in these regions belong to two taxonomic families²⁴⁻²⁷:

- *Viperidae*—African adders and bush vipers, Asian pit vipers, mamushis, habus, and New World rattlesnakes, moccasins, bushmasters, and lanceheads
- *Elapidae*—African and Asian cobras, African mambas, African rinkhals, Asian kraits, Australian and Papuan venomous snakes, Asian and New World coral snakes and sea snakes

Venomous snakes inject venom during a bite using specialised grooved or hollow teeth called fangs. The fangs are connected to venom glands on each side of the upper jaw via a duct.²⁸ Viperids usually have long foldable front-fangs, while those in elapids are short and fixed (fig 1).²⁸ Depending on fang length, venom is introduced either subcutaneously or intramuscularly.³

Snakebite affects between 1.8 to 2.7 million people worldwide each year, and it is estimated to cause between 80 000 and 138 000 deaths.^{1 2} A mixture of toxins (venom) is injected into the body following bite by a venomous snake.³ Envenoming can be a highly dynamic clinical event. Symptoms can progressively worsen to a life-threatening emergency. Snakebites can have long term physical sequelae such as amputation, paralysis and disability, and psychological health consequences.⁴⁻⁷

Snakebite envenoming is more common in South and South-East Asia (2 million annually), sub-Saharan Africa (420 000) and Latin America (150 000).^{1 2} These regions also report a high burden of deaths from snakebite (100 000, 32 000, and 5000 deaths respectively) possibly due to poor access to medical aid.^{1 2} Delayed diagnosis and treatment can worsen prognosis.⁸⁻¹¹ The World Health Organization recognised snakebite as a neglected tropical disease in 2017 and called for concerted global action to reduce deaths and disability.¹²

In this clinical update, we present an approach to evaluation and management of snakebites for primary care providers in resource-limited settings in endemic regions. The principles of management are broadly similar, but it is beyond the scope of this article to cover clinical syndromes and management for the varied snake species globally.

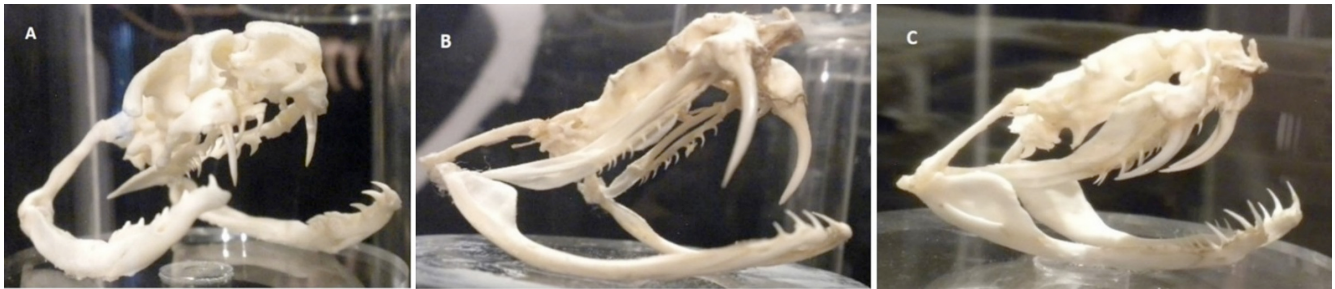

Fig 1 | Difference in fangs between elapids and viperids. A) Elapids have short, fixed, front fangs. B&C) Vipers have much longer and retractable front fangs. (Photos courtesy of Ahmad Khaldun Ismail)

Some snakes with fangs towards the back of the mouth (“non-front-fanged colubroids” such as African boomslang and vine snakes, South American racers, and Asian yamakagashis) and the burrowing asps (or stiletto snakes) whose unique jaw kinesis coupled with exceptional neck flexure allow for a single protruding fang to be jabbed sideways or backwards, can also cause envenoming.^{3 28 29} Spitting cobras and rinkhals can eject venom over several metres, often delivering venom droplets into the eyes of the animal or human perceived to be a threat.^{30–32}

What are the clinical effects of snakebite?

Not all people with a snakebite have clinical symptoms. Often bites are by non-venomous snakes. Sometimes venomous snakes do not inject venom during a bite.³³

Clinical manifestations vary between species of snakes (see box 1).³ Some toxins in venom exert local effects such as swelling, blistering, bruising, and necrosis at the bite site.^{24 25} Other toxins can be distributed systemically through lymphatics and blood vessels and act at distant sites. See supplementary text for an overview of important sites and pathophysiology of venom-toxin action. Common systemic effects include bleeding, paralysis, generalised rhabdomyolysis, and acute kidney injury. Venom injection deep into a limb can cause tissue swelling in the tightly constrained space and compromise neurovascular function.^{54 55} This manifests as “acute compartment syndrome.”^{24 25 31}

Box 1: Clinical effects of snakebite

Local effects

- *Bite site*—Swelling, blistering, bruising, necrosis (usual after bites by cobras and vipers, with some exceptions in each family, and burrowing asps)^{24 25}
- *Acute compartment syndrome after deep bite into a limb*—Intense pain, abnormal sensations, or a cold, pulseless, immobile limb^{24 25}
- *Venom ophthalmia from entry of venom droplets or spray into the eyes*—Intense pain, redness, blepharitis, blepharospasm, and corneal erosions³¹

Systemic effects

- *Vascular*—Envenoming by most viperid and Australopapuan elapid species and some non-front-fanged colubroids can trigger clotting failure, platelet abnormalities, and vessel wall damage.^{34–36} Effects range from clotting test abnormalities to mild bite site or mucosal bleeds to severe spontaneous systemic or intracranial haemorrhage^{24 25}
- *Shock*—From bleeding or plasma extravasation systemically or into the swollen, bitten limb, myocardial dysfunction, pituitary bleeds, vasodilation, sepsis, and anaphylaxis^{29 36–42}

- *Neuromuscular*—Most elapid and some viperid venoms can cause paralysis by action at the nerve (presynaptic) or muscle fibre (postsynaptic) of the neuromuscular junction.^{24 25} Weakness of eye muscles initially present as ptosis, diplopia, and blurred vision. This is followed by sequential weakness of bulbar (dysphagia, dysphonia, and drooling), neck, respiratory, and limb muscles⁴³
- Generalised muscle destruction is caused by envenoming by sea snakes and some elapid and viperid species.^{24 25} This manifests as muscle pain and tenderness, especially of the neck, trunk, and proximal limbs with dark urine²⁹
- Acute kidney injury likely results from secondary effects such as hypotension, fibrin-platelet microthrombi in capillaries and arterioles, and immune or haem related tubular damage, or directly from effect of venom^{44–53}

How do patients present?

Patients usually give a history of being bitten by a snake, except those who experience painless nocturnal bites by kraits while asleep.^{22 56 57} Patients are often fearful and anxious. Occasionally, painful bites may be mistaken for a puncture wound from a thorn or sharp stone and be ignored initially.⁵⁸ Some patients, especially children, bitten by highly venomous snakes, may present with cardiovascular collapse, unconsciousness, bleeding, paralysis, or respiratory failure and may not provide a clear history of snakebite.^{44 59} It is important to consider envenoming in these situations in regions where snakebites are common.^{24 25}

Nausea, vomiting, abdominal pain, and headache are non-specific symptoms but must be monitored as these may herald serious complications such as uraemia, acute pituitary or intracranial bleeds, and anaphylaxis.²⁴

What first aid can be provided?

Reassure the person about prompt first aid and medical assistance to allay fears. Arrange for rapid transport to the nearest medical facility, preferably with access to antivenom and critical care support.⁶⁰

Immobilise the person, and especially the bitten limb to slow venom spread.²⁴ Remove rings and other tight objects around the limb.⁶¹ A systematic review identified pressure immobilisation with an elastic bandage or pad (at a comfortable pressure) at the bite site as an effective first aid measure to slow venom spread, but the quality of evidence was very low.^{62 63} Its use is variable, and it is discouraged in most practice and guidelines because of the uncertainty of benefit and possibility of worsening local tissue damage.^{15 29 62 64–67} However, pressure immobilisation is generally recommended for neurotoxic elapid bites in some regions.⁶⁸ Its

clinical efficacy and risk of worsening soft tissue injury in local envenoming have not been adequately assessed.^{24 29 66 69} A small study (15 patients) in Myanmar found that pressure pads were effective in reducing venom spread in Russell's viper bite, and local effects after pad application were no more severe than those before treatment.⁷⁰

Tourniquets can cause severe local damage and gangrene and must not be used.^{24 25} It is common for communities to resort to traditional therapies such as wound incisions, cauterisation, and application of herbs, minerals, or animal excrement. These can delay access to effective treatment and may cause more harm.^{15 71 72} Irrigate eyes with copious amounts of water if there is exposure to venom.³¹

What to cover on initial assessment?

Rural and remote primary care centres are often the first point of medical aid for people with a snakebite. Laboratory and intensive care services at such facilities are often limited. A competent clinical assessment is vital to guide management and referral decisions.^{14 73 76}

Snakebite envenoming can quickly worsen into a life-threatening emergency. Assess vital parameters to identify if the patient is critical or at risk for shock, respiratory failure, and cardiac arrest.^{24 25} Published severity scores for snakebite are unreliable.³ The Glasgow coma scale score and pupillary reactions can be misleading in patients with advanced paralysis who are unable to open their eyes or respond to painful stimuli and should be avoided in these circumstances.²⁴

History

Reassure clinically stable patients. Ask about their symptoms to determine the presence, nature, and extent of envenoming. Details about the site, circumstances, and timing of the bite can reflect distinctive features of epidemiology, habitats, and periods of activity of medically important snakes locally and help infer likely biting-species.^{3 24 25}

Inquire about medications, substance use, and comorbidities as these can influence diagnosis and outcomes. Recent ethanol or recreational drug use may modify presenting symptoms. Antiplatelets or anticoagulants may worsen bleeding and interfere with key blood tests. Shock in patients with pre-existing coronary artery disease can precipitate a myocardial infarction.³

Examination

Bite site—Look for fang marks, retained fangs, bleeding, swelling, bruising, discoloration, and blisters.²⁴ Fang marks do not confirm snakebite since bites by lizards, fish, rodents, large spiders, and some insects and thorns also leave paired punctures.³ Their absence does not preclude envenoming, as many snake species produce faint or undetectable bites.^{22 24 25 56 77 78} Raised vertical, red, tender

streaks on the bitten limb suggest lymphangitis.^{3 24 25} Regional lymph nodes may be enlarged and tender with bruised overlying skin.^{3 24 25} Note any tourniquets, ligatures, wound incisions or cauterisation, and local traditional remedies as these may lead to specific complications requiring management.^{24 25} For instance, tourniquets and ligatures, if left on for long, can cause severe local damage including ischaemia, necrosis, and gangrene. Similarly, incisions and local applications can lead to local bacterial infections, sepsis, and tetanus.^{18 79 80}

Systemic examination—Look for signs of coagulopathy such as sub-conjunctival, retinal, nasal, and gingivobuccal bleeds, ecchymoses and internal haemorrhage (such as intracranial, pericardial, pleural, and retroperitoneal).^{24 25} Assess extraocular movements, bulbar function, and muscle power.^{24 25} Look for ptosis, muscle tenderness, and jaw stiffness.^{24 25} Jaw stiffness is a prominent but often overlooked feature in sea snake envenoming that, unlike trismus, can be reduced by sustained pressure on the lower jaw.⁸¹

Identifying snake species—Occasionally patients or accompanying persons may bring the killed snake for identification or have a picture of it. A herpetologist can be consulted to help identify the species.²⁹ Identification of snakes based on description by victims or recognition from pictures is often unreliable.^{29 82 83} Identifying biting-species helps avoid unnecessary antivenom in patients bitten by non-venomous snakes or by species whose venoms are not neutralised by available products. It can help select appropriate antivenom in countries with products specific against single species and anticipate clinical progression. However, delaying emergency treatment until the species is identified is unnecessary.

Knowledge of local snake species, comparison of clinical effects in the patient against established species-specific syndromes, and consideration of the circumstances and timing of the incident can help infer likely biting species.^{29 82} This approach is widely used to guide treatment with polyspecific antivenom in endemic areas of Africa and Asia.^{82 84} Snake identification tests based on venom antigen are valuable research tools but are currently unavailable for routine clinical use except in Australia.⁸⁵

What tests can be performed?

Perform a baseline 20-minute whole blood clotting test (20WBCT) to screen for coagulopathy in patients without overt bleeding. The 20WBCT is a simple, rapid, and inexpensive bedside test to screen for and monitor coagulopathy in areas with limited access to emergency laboratory facilities.^{29 86 87} Collect a sample of venous blood from the patient and place a few millilitres into a clean dry test tube. Leave it undisturbed for 20 minutes at ambient temperature. Unclotted blood that runs out or a friable clot that readily breaks down on tipping the tube once at 20 minutes indicates a possible clotting disorder (fig 2).^{24 25}




Fig 2 | Examples of the 20-minute whole blood clotting test. A) With normal blood, a clot is seen at 20 minutes after sample collection. B) Incoagulable blood at 20 minutes, from a patient with Russell's viper envenoming

Most clinical validation studies on the 20WBCT report a sensitivity of 82-89% and specificity of 82-98%. One study indicated that the test might potentially miss one of every five coagulopathic patients.^{88 89} A recent systematic review and meta-analysis of the 20WBCT to evaluate its accuracy in detecting coagulopathy (defined as INR >1.4 or fibrinogen <100 mg/dL) revealed an 84% sensitivity and 91% specificity using the international normalised ratio (INR) as reference standard and 72% sensitivity and 94% specificity using plasma fibrinogen as reference standard.⁹⁰ The test was less sensitive in detecting milder coagulopathy (median INR for patients with a false negative 20WBCT was 1.9 (IQR 1.6 to 12, skewness of 1.06 and kurtosis of -0.83) and resolution of coagulopathy following antivenom administration (sensitivity 5% to 67%).

In settings with laboratory support, additional tests might include a complete blood count, coagulation studies, and biochemical assays including creatinine phosphokinase (CPK), serum creatinine, blood urea, and electrolytes.³ A low haematocrit usually occurs with blood loss. Higher than normal values may indicate haemoconcentration from systemic plasma extravasation. Peripheral neutrophilic leucocytosis represents a general inflammatory response and confirms systemic envenoming. Severe

thrombocytopenia contributes to bleeding diatheses. It may indicate microangiopathic haemolysis when accompanied by schistocytes in the blood film and acute kidney injury. Prothrombin and activated partial thromboplastin times, D dimer, fibrinogen, and fibrin degradation products are more sensitive indicators of venom induced clotting disturbances. Blood urea, serum creatinine, and electrolyte concentrations help screen and monitor acute kidney injury. CPK levels above 10 000 units/L indicate severe rhabdomyolysis. Unexplained hypoglycaemia (venous blood glucose <55 mg/dL) can be an important clue to acute hypopituitarism following snake envenoming.⁹¹

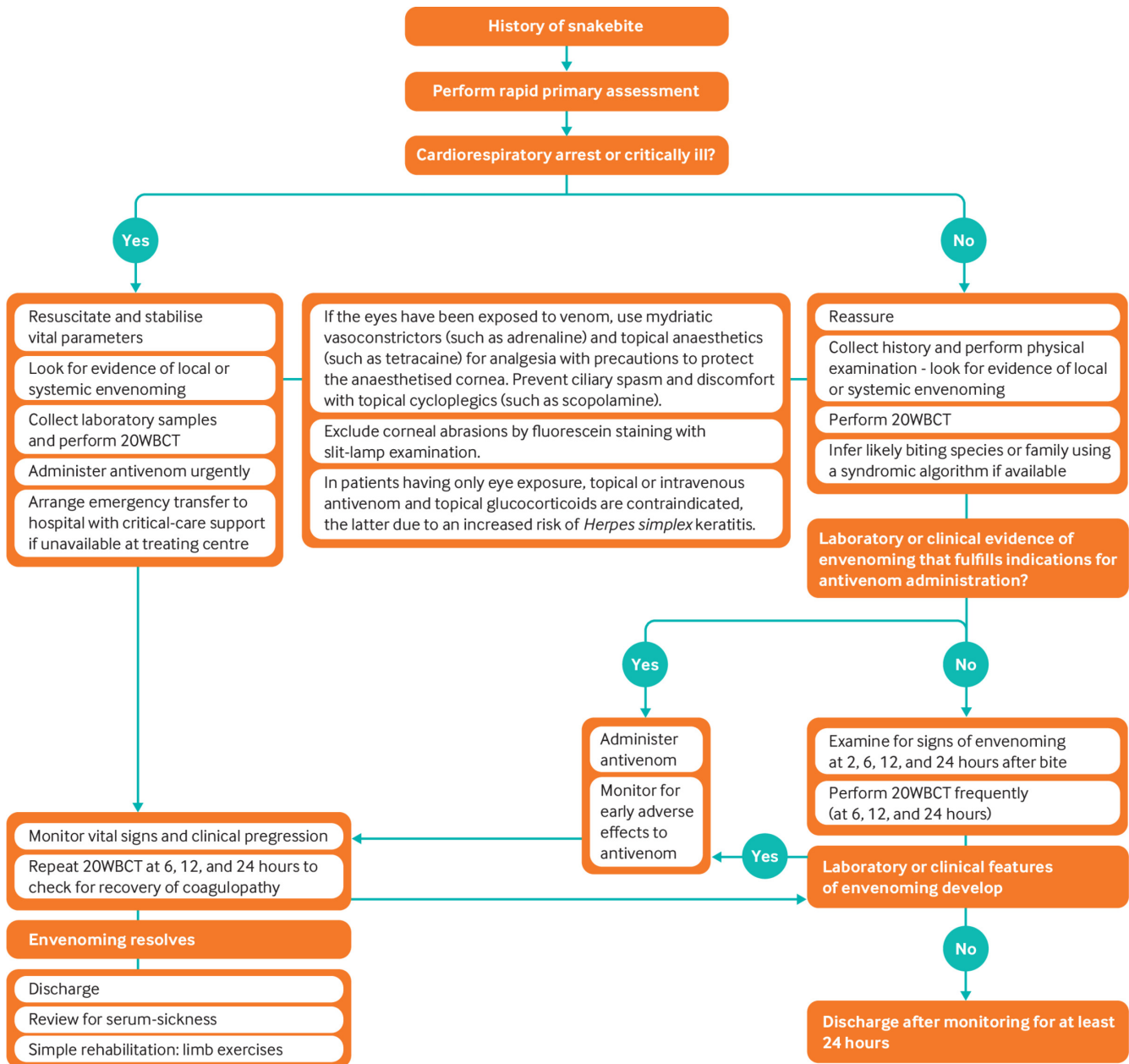
How is snakebite managed?

Resuscitation and supportive care

Admit all snakebite patients for observation for a minimum of 24 hours. The onset of symptoms may be delayed but can worsen rapidly. Inform patients and/or their relatives about potential complications, treatment, and critical-care measures using simple language, after emergency medical stabilisation. If required, explain the need for referral clearly.

Promptly manage airway obstruction, respiratory paralysis, and shock by restoring airway, oxygen, intubation, and assisted ventilation as needed, and intravenous fluids. Figure 3 summarises the management of snakebite. Choose sites of venous access such as the hands, wrists, and in some cases the feet where haemostasis by external pressure is most likely to succeed.²⁴ Avoid central

venous or arterial punctures before establishing a negative 20WBCT.²⁴ Ensure that an intravenous line and resuscitation facilities are in place before releasing tourniquets, since this may trigger pronounced clinical deterioration.⁹² Avoid aspirin or other NSAIDs to control pain as they can exacerbate bleeding diathesis.³



20WBCT = 20-minute whole blood clotting test

Fig 3 | Flowchart for the management of snakebite

Monitor vital parameters and urine output at regular intervals in all patients. The 20WBCT can be repeated as it is sometimes negative initially, and coagulopathy may be detected later.^{24 25}

Antivenom

Guidelines from the WHO recommend antivenom treatment for patients with shock, spontaneous systemic bleeding, uncoagulable blood, neurotoxicity, black urine, acute kidney injury, rapidly

progressive local swelling, and bites by species known to cause local necrosis and digital bites.^{24 25}

Antivenoms are whole or fragmented immunoglobulins fractionated from the plasma of domesticated animals hyper-immunised with venom from one or more snake species over variable periods.⁹³ They are highly specific and will neutralise only the venoms used in their production and those of a few closely related species.⁹³ Polyspecific

antivenoms are raised against a mixture of venoms from more than one species. Antivenoms raised against venom from a single species are monospecific.⁹³

Early administration of antivenom prevents or limits haemodynamic alterations, progression of coagulopathy to clinically overt bleeding, postsynaptic neurotoxicity, myotoxicity, acute kidney injury, and local tissue damage.^{24 25 94} Physiological levels of clotting factors are at least partially restored within a median of six hours with sufficient doses of specific antivenoms.^{45 95 -101}

Robust clinical data on the safe and effective initial dose of antivenom are lacking for most products.¹⁰² Clinicians often rely on manufacturers' recommendations provided as package inserts or labels, but these can be unreliable.^{103 104} We suggest following national protocols or standard regional guidelines for dose.^{24 25} Administration is always intravenous, as bolus or diluted in saline solution over 10-60 minutes, at the same dose for adults and children.²⁴ Repeat administration of antivenom if bleeding persists, if weakness or cardiovascular signs worsen within two hours, or if a 20WBCT is positive at six hours after antivenom administration.³

The effectiveness of antivenoms in treating established neurotoxicity, soft tissue damage, and acute kidney injury is not established.^{24 25 94 105 106} Additional treatments are indicated for these.

Other treatments

Neostigmine with atropine is a potentially useful adjunct in patients bitten by snakes such as some cobras with postsynaptic neurotoxins in their venom. Its use must never delay or preclude antivenom treatment or intubation.²⁴

Administer a tetanus toxoid booster in all patients except in those with coagulopathy, in which case injection is postponed until haemostasis is achieved.³ Aspirate large tense bullae to facilitate nursing the bitten limb, pre-empt spontaneous rupture, and prevent secondary infection. Broad spectrum antibiotics are indicated only if the wound has been incised or there are signs of necrosis, wound infection, or abscess formation.³ Surgical debridement or amputation of gangrenous digits or limbs and skin grafting may be needed.^{24 25} Fasciotomies are rarely justified since compartment pressures usually remain within normal limits.^{3 107}

Risk of adverse reactions with antivenom

Monitor patients for adverse reactions in the first two hours of antivenom administration (box 2).²⁹ Anaphylaxis or pyrogenic reactions occur early (within minutes or hours). Mechanistic studies suggest that most events are not IgE mediated and thus cannot be accurately predicted by skin tests for immediate hypersensitivity.¹⁰⁹ However, their incidence and severity can be reduced by a prophylactic subcutaneous injection of low dose adrenaline.^{108 110} Pyrogenic reactions result from product contamination during manufacture.¹¹¹

Box 2: Clinical features and frequency of adverse reactions to antivenom

Anaphylaxis symptoms

- Itching
- Urticaria
- Nausea, vomiting, abdominal pain, and diarrhoea
- Life threatening shock, bronchospasm, and angioedema¹⁰⁸

Pyrogenic reactions

- These present with fever, rigors, and vasodilation with or without hypotension

Late or serum-sickness type reactions²⁴

- Fever
- Nausea, vomiting, diarrhoea
- Itching or recurrent wheals
- Joint and muscle aches or joint swelling
- Lymph node enlargement
- Proteinuria and kidney disease

Depending on the dose, speed of administration, and product quality, the risk of any early reaction varies from 3% to more than 80% in studies from Latin America and South Asia. About 5-10% of such events are associated with life threatening consequences.^{29 98 108 110 112} The incidence of fatal reactions is unclear because of confusion with symptoms of envenoming, but some have been reported.¹¹²

Treat anaphylaxis at the earliest sign.^{24 25} Suspend antivenom administration and inject adrenaline intramuscularly, ideally into the upper lateral thigh.^{24 25} Additional treatment includes intravenous antihistamines and glucocorticoids and inhaled bronchodilators for bronchospasm.^{24 25} Anaphylaxis can recur, and glucocorticoids do not prevent recurrence.¹¹² On resolution of the episode, cautiously resume antivenom in patients with a definite indication for continued treatment.^{24 25} Treat pyrogenic reactions with physical cooling, antipyretics, and intravenous fluids.^{24 25}

Late reactions may manifest a week after administration.^{108 111 113} Their incidence varies widely from 5% to 56% in observational studies and trials using differing diagnostic criteria.¹⁰⁸ WHO guidelines recommend a five-day course of oral antihistamines for those with serum-sickness type late reactions, and a five-day course of prednisolone in those who fail antihistamine therapy after the first two days.^{24 25}

Whom to refer?

Patients with persistent bleeding despite repeated antivenom treatment or having respiratory and renal failure may require urgent supportive measures such as blood transfusion, mechanical ventilation, and renal replacement therapy respectively.^{24 25} If these are not available, arrange for transfer to a specialised centre. Patients with substantial bleeding, worsening paralysis, dropping urine output, refractory shock, anaphylaxis non-responsive to adrenaline, or compartment syndrome may also require specialist management and intensive care.²⁴

Having contact details of emergency transport and the referral centre readily available can avoid delays. Inform the receiving hospital about the patient's condition over the phone and send a referral letter with details of assessment and treatment.¹¹⁴

What to cover on discharge and follow-up?

Patients who are clinically stable or asymptomatic with persistently negative 20WBCT after 24 hours may be discharged. Educate patients and their families on snakebite prevention and first aid, preferably using printed leaflets with clear visually represented information and minimal reliance on text.^{3 12}

Inform patients who have received antivenom to report late adverse reactions. Arrange a follow-up after two weeks to review late reactions and sequelae.

What are the long-term sequelae of snakebite?

There is insufficient data on long term sequelae after a snakebite.⁶ Amputations following snakebite-related soft tissue injuries range from 5908 to 14 614 annually in sub-Saharan Africa, based on a meta-analysis of data published between 1970 and 2010.⁴ Even in patients not requiring amputations, tissue loss may result in chronic ulcers, malignant transformation, and scarring.²⁹ Musculoskeletal sequelae such as contractures, wasting, and joint stiffness affected up to 3% of snakebite survivors in a study of 816 patients in Sri Lanka.¹¹⁵ Cerebrovascular accidents result in persisting limb weakness and visual or cognitive impairment.²⁹ Eye exposure to venom can result in blindness.³¹ Some patients with acute kidney injury may progress to chronic renal failure.¹¹⁶⁻¹²⁰ Limited data from case reports and observational studies from South Asia indicate that chronic hypopituitarism, a sequel of acute pituitary haemorrhage, can present as fatigue, arrested puberty, amenorrhoea, and hypothyroidism as late as 10 years after the bite.^{37 91 121-123} Snakebite survivors also have higher rates of post-traumatic stress disorder and depression compared with matched controls.^{5 7} Ensuring access to physiotherapy, psychological services, and specialists, as needed, can be essential in managing long term sequelae of snake bite.

Areas for future research

- High-quality randomised controlled clinical trials evaluating the feasibility and effectiveness of pressure immobilisation in bites by different snake species
- Large, well designed clinical trials to establish safety, effectiveness, and optimal dose of antivenoms. The risks of anaphylaxis and sensitisation to animal proteins in antivenoms place ethical limitations on conventional phase I/II designs.¹²⁴ Some literature suggests that model based adaptive designs, as used to test anticancer drugs, could be safer alternatives for antivenom testing^{95 102 124}
- Studies on envenoming syndromes to establish species-syndrome correlation and aid early identification of snake species
- Clinical trials to evaluate the effectiveness and safety of adjunctive treatment options including small molecular therapeutics such as secretory phospholipase A2 inhibitors (varespladib/varespladib-methyl), matrix metalloproteinase inhibitors (batimastat and marimastat), and peptide and oligomer based technologies such as toxin-specific monoclonal antibodies and aptamers^{125 126}
- Observational studies with long post-discharge follow-up to determine the prevalence, severity, clinical progression, and risk factors of long term sequelae from snakebite

Additional resources

- Information on the spatial ecology of medically important venomous snakes, antivenom products, and the location of antivenom manufacturers by country or region can be obtained from the World Health Organization's Snakebite Information and Data Platform <https://www.who.int/teams/control-of-neglected-tropical-diseases/snakebite-envenoming/snakebite-information-and-data-platform>.
- Information on envenoming profiles of different snakes and their management can be obtained from the following sites:
 - African snakebites—WHO. *Guidelines for the prevention and clinical management of snakebite in Africa*. 2010. <https://apps.who.int/iris/handle/10665/204458>
 - South-East Asian snakebites—WHO. *Guidelines for the management of snakebites*. 2nd ed. 2016. <https://apps.who.int/iris/handle/10665/249547>

- Global snakes database—University of Adelaide. Clinical toxicology resources: Snakes. www.toxinology.com

Education into practice

- Think about the last time you treated a patient with snakebite. Reflect on the challenges you encountered while diagnosing and treating envenoming. What changes, if any, might you make to your approach next time?
- How do you review a snakebite patient as an outpatient discharge? Think about common persisting physical and psychological problems that you might have noticed during review. To what extent was the patient able to share difficulties in returning to routine life? How might you involve the patient in making decisions about long term?

How patients were involved in the creation of this article

No patients were involved in the creation of this article.

Contributors: RR formulated and wrote the initial draft. All authors searched the literature, framed manuscript content, contributed to critical revisions and approved of the final version. RR is the guarantor of this article.

The corresponding author attests that all listed authors meet authorship criteria and that no others meeting the criteria have been omitted. The authors are fully responsible for the contents and editorial decisions for this manuscript.

Competing interests: We have read and understood *BMJ* policy on declaration of interests and have no relevant interests to declare.

Provenance and peer review: Commissioned; externally peer reviewed.

We thank Abdulrazaq Habib, Bayero University, Kano, Nigeria; Colin J Forsyth, Drugs for Neglected Diseases initiative-North America; Ahmad Khaldun Ismail, Profesor Madya, Department of Emergency Medicine, Faculty of Medicine, Universiti Kebangsaan Malaysia, Kuala Lumpur, Malaysia; José María Gutiérrez, Instituto Clodomiro Picado, Facultad de Microbiología, Universidad de Costa Rica, Costa Rica; and Scott A Weinstein, Women's and Children's Hospital, North Adelaide, Australia for their instructive comments on this manuscript.

Supplementary illustrations on the pathophysiology of venom-toxin action were created with BioRender.com

- 1 Chippaux JP. Snake-bites: appraisal of the global situation. *Bull World Health Organ* 1998;76:515-24. PMID: 9868843
- 2 Kasturiratne A, Wickremasinghe AR, de Silva N, et al. The global burden of snakebite: a literature analysis and modelling based on regional estimates of envenoming and deaths. *PLoS Med* 2008;5:e218. doi: 10.1371/journal.pmed.0050218 PMID: 18986210
- 3 Gutiérrez JM, Calvete JJ, Habib AG, Harrison RA, Williams DJ, Warrell DA. Snakebite envenoming. *Nat Rev Dis Primers* 2017;3:17063. doi: 10.1038/nrdp.2017.63. PMID: 28905944
- 4 Chippaux J-P. Estimate of the burden of snakebites in sub-Saharan Africa: a meta-analytic approach. *Toxicon* 2011;57:586-99. doi: 10.1016/j.toxicon.2010.12.022 PMID: 21223975
- 5 Williams SS, Wijesinghe CA, Jayamanne SF, et al. Delayed psychological morbidity associated with snakebite envenoming. *PLoS Negl Trop Dis* 2011;5:e1255. doi: 10.1371/journal.pntd.0001255 PMID: 21829741
- 6 Waiddyanatha S, Silva A, Siribaddana S, Isbister GK. Long-term effects of snake envenoming. *Toxins (Basel)* 2019;11:E193. doi: 10.3390/toxins11040193 PMID: 30935096
- 7 Habib ZG, Salihu AS, Hamza M, et al. Posttraumatic stress disorder and psycho-social impairment following snakebite in Northeastern Nigeria. *Int J Psychiatry Med* 2021;56:97-115. doi: 10.1177/0091217420913400 PMID: 32216497
- 8 Ameade EPK, Bonney I, Boateng ET. Health professionals' overestimation of knowledge on snakebite management, a threat to the survival of snakebite victims—A cross-sectional study in Ghana. *PLoS Negl Trop Dis* 2021;15:e0008756. doi: 10.1371/journal.pntd.0008756 PMID: 33465084
- 9 Michael GC, Grema BA, Aliyu I, et al. Knowledge of venomous snakes, snakebite first aid, treatment, and prevention among clinicians in northern Nigeria: a cross-sectional multicentre study. *Trans R Soc Trop Med Hyg* 2018;112:47-56. doi: 10.1093/trstmj/try028 PMID: 29617989
- 10 Sapkota S, Pandey DP, Dhakal GP, Gurung DB. Knowledge of health workers on snakes and snakebite management and treatment seeking behavior of snakebite victims in Bhutan. *PLoS Negl Trop Dis* 2020;14:e0008793. doi: 10.1371/journal.pntd.0008793 PMID: 33253152
- 11 Taieb F, Dub T, Madec Y, et al. Knowledge, attitude and practices of snakebite management amongst health workers in Cameroon: Need for continuous training and capacity building. *PLoS Negl Trop Dis* 2018;12:e0006716. doi: 10.1371/journal.pntd.0006716 PMID: 30359385

- 12 World Health Organization. *Snakebite envenoming—A strategy for prevention and control*. 2019. <https://www.who.int/publications/item/9789241515641>.
- 13 Kasturiratne A, Pathmeswaran A, Wickremasinghe AR, et al. The socio-economic burden of snakebite in Sri Lanka. *PLoS Negl Trop Dis* 2017;11:e0005647. doi: 10.1371/journal.pntd.0005647 pmid: 28683119
- 14 Cruz LS, Vargas R, Lopes AA. Snakebite envenomation and death in the developing world. *Ethn Dis* 2009;19(Suppl 1):S1-42, 6. pmid: 19484874
- 15 Alirol E, Sharma SK, Bawaskar HS, Kuch U, Chappuis F. Snake bite in South Asia: a review. *PLoS Negl Trop Dis* 2010;4:e603. doi: 10.1371/journal.pntd.0000603 pmid: 20126271
- 16 Harrison RA, Hargreaves A, Wagstaff SC, Faragher B, Lalloo DG. Snake envenoming: a disease of poverty. *PLoS Negl Trop Dis* 2009;3:e569. doi: 10.1371/journal.pntd.0000569 pmid: 20027216
- 17 Chippaux J-P. Incidence and mortality due to snakebite in the Americas. *PLoS Negl Trop Dis* 2017;11:e0005662. doi: 10.1371/journal.pntd.0005662 pmid: 28636631
- 18 Pochanugool C, Wildde H, Bhangnada K, et al. Venomous snakebite in Thailand. II: Clinical experience. *Mil Med* 1998;163:318-23. doi: 10.1093/milmed/163.5.318 pmid: 9597849
- 19 Aye K-P, Thanachartwet V, Soe C, et al. Clinical and laboratory parameters associated with acute kidney injury in patients with snakebite envenomation: a prospective observational study from Myanmar. *BMC Nephrol* 2017;18:92. doi: 10.1186/s12882-017-0510-0 pmid: 28320277
- 20 Laohawiriyakamol S, Sangkhathat S, Chiengkriwate P, Patrapinyokul S. Surgery in management of snake envenomation in children. *World J Pediatr* 2011;7:361-4. doi: 10.1007/s12519-011-0282-8 pmid: 21877258
- 21 Ralph R, Sharma SK, Faiz MA, et al. The timing is right to end snakebite deaths in South Asia. *BMJ* 2019;364:k5317. doi: 10.1136/bmj.k5317 pmid: 30670457
- 22 Tongpoo A, Sriapha C, Pradoo A, et al. Krait envenomation in Thailand. *Ther Clin Risk Manag* 2018;14:1711-7. doi: 10.2147/TCRM.S169581 pmid: 30271155
- 23 Ochoa-Avilés A, Heredia-Andino OS, Escandón SA, et al. Viperidae snakebites in Ecuador: A review of epidemiological and ecological aspects. *Toxicon X* 2020;7:100051. doi: 10.1016/j.toxcx.2020.100051 pmid: 32760910
- 24 World Health Organization. *Guidelines for the management of snakebites*, 2nd ed. 2016. <https://apps.who.int/iris/handle/10665/249547>.
- 25 World Health Organization. *Guidelines for the prevention and clinical management of snakebite in Africa*. 2010. <https://apps.who.int/iris/handle/10665/204458>.
- 26 Hsiang AY, Field DJ, Webster TH, et al. The origin of snakes: revealing the ecology, behavior, and evolutionary history of early snakes using genomics, phenomics, and the fossil record. *BMC Evol Biol* 2015;15:87. doi: 10.1186/s12862-015-0358-5 pmid: 25989795
- 27 Pyron RA, Burbrink FT, Wiens JJ. A phylogeny and revised classification of Squamata, including 4161 species of lizards and snakes. *BMC Evol Biol* 2013;13:93. doi: 10.1186/1471-2148-13-93 pmid: 23627680
- 28 Kerkkamp HMI, Casewell NR, Vonk FJ. Evolution of the snake venom delivery system. In: Malhotra A, Gopalakrishnakone P, eds. *Evolution of venomous animals and their toxins*. Springer Netherlands, 2017: 303-16. doi: 10.1007/978-94-007-6458-3_11.
- 29 Warrell DA. Snake bite. *Lancet* 2010;375:77-88. doi: 10.1016/S0140-6736(09)61754-2 pmid: 20109866
- 30 Young BA, Dunlap K, Koenig K, Singer M. The buccal buckle: the functional morphology of venom spitting in cobras. *J Exp Biol* 2004;207:3483-94. doi: 10.1242/jeb.01170 pmid: 15339944
- 31 Chu ER, Weinstein SA, White J, Warrell DA. Venom ophthalmia caused by venoms of spitting elapid and other snakes: Report of ten cases with review of epidemiology, clinical features, pathophysiology and management. *Toxicon* 2010;56:259-72. doi: 10.1016/j.toxicon.2010.02.023 pmid: 20331993
- 32 Westhoff G, Tzschätzsch K, Bleckmann H. The spitting behavior of two species of spitting cobras. *J Comp Physiol A Neuroethol Sens Neural Behav Physiol* 2005;191:873-81. doi: 10.1007/s00359-005-0010-8 pmid: 16007458
- 33 Pucca MB, Knudsen C, S Oliveira I, et al. Current knowledge on snake dry bites. *Toxins (Basel)* 2020;12:E668. doi: 10.3390/toxins12110668 pmid: 33105644
- 34 Isbister GK, Scorgie FE, O'Leary MA, Seldon M, Brown SG, Lincz LFASP Investigators. Factor deficiencies in venom-induced consumption coagulopathy resulting from Australian elapid envenomation: Australian Snakebite Project (ASP-10). *J Thromb Haemost* 2010;8:2504-13. doi: 10.1111/j.1538-7836.2010.04050.x pmid: 20831619
- 35 Rucavado A, Soto M, Escalante T, Loría GD, Arni R, Gutiérrez JM. Thrombocytopenia and platelet hypoaggregation induced by Bothrops asper snake venom. Toxins involved and their contribution to metalloproteinase-induced pulmonary hemorrhage. *Thromb Haemost* 2005;94:123-31. doi: 10.1160/TH05-02-0112 pmid: 16113795
- 36 Gutiérrez JM, Escalante T, Rucavado A, Herrera C. Hemorrhage caused by snake venom metalloproteinases: a journey of discovery and understanding. *Toxins (Basel)* 2016;8:93. doi: 10.3390/toxins8040093 pmid: 27023608
- 37 Tun-Pe Phillips RE, Warrell DA, et al. Acute and chronic pituitary failure resembling Sheehan's syndrome following bites by Russell's viper in Burma. *Lancet* 1987;2:763-7. doi: 10.1016/S0140-6736(87)92500-1 pmid: 2888987
- 38 Slagboom J, Kool J, Harrison RA, Casewell NR. Haemotoxic snake venoms: their functional activity, impact on snakebite victims and pharmaceutical promise. *Br J Haematol* 2017;177:947-59. doi: 10.1111/bjh.14591 pmid: 28233897
- 39 Péterfi O, Boda F, Szabó Z, Ferencz E, Bába L. Hypotensive snake venom components—a mini-review. *Molecules* 2019;24:E2778. doi: 10.3390/molecules24152778 pmid: 31370142
- 40 Camargo ACM, Ianzer D, Guerreiro JR, Serrano SMT. Bradykinin-potentiating peptides: beyond captopril. *Toxicon* 2012;59:516-23. doi: 10.1016/j.toxicon.2011.07.013 pmid: 21835190
- 41 Silva A, Pilapitiya S, Siribaddana S. Acute myocardial infarction following a possible direct intravenous bite of Russell's viper (Daboia russelii). *BMC Res Notes* 2012;5:500. doi: 10.1186/1756-0500-5-500 pmid: 22971617
- 42 Jeevagan V, Katulanda P, Gnanathanan CA, Warrell DA. Acute pituitary insufficiency and hypokalaemia following envenoming by Russell's viper (Daboia russelii) in Sri Lanka: Exploring the pathophysiological mechanisms. *Toxicon* 2013;63:78-82. doi: 10.1016/j.toxicon.2012.11.012 pmid: 23212048
- 43 Ranawaka UK, Lalloo DG, de Silva HJ. Neurotoxicity in snakebite—the limits of our knowledge. *PLoS Negl Trop Dis* 2013;7:e2302. doi: 10.1371/journal.pntd.0002302 pmid: 24130909
- 44 Allen GE, Brown SGA, Buckley NA, et al. ASP Investigators. Clinical effects and antivenom dosing in brown snake (Pseudonaja spp.) envenoming—Australian snakebite project (ASP-14). *PLoS One* 2012;7:e53188. doi: 10.1371/journal.pone.0053188 pmid: 23300888
- 45 Myint-Lwin Warrell DA, Phillips RE, Tin-Nu-Swe Tun-Pe Maung-Maung-Lay. Bites by Russell's viper (Vipera russelli siamensis) in Burma: haemostatic, vascular, and renal disturbances and response to treatment. *Lancet* 1985;2:1259-64. doi: 10.1016/S0140-6736(85)91550-8 pmid: 2866333
- 46 Alves EC, Sachett JAG, Sampaio VS, et al. Predicting acute renal failure in Bothrops snakebite patients in a tertiary reference center, Western Brazilian Amazon. *PLoS One* 2018;13:e0202361. doi: 10.1371/journal.pone.0202361 pmid: 30118505
- 47 Pinho FMO, Zanetta DMT, Burdman EA. Acute renal failure after Crotalus durissus snakebite: a prospective survey on 100 patients. *Kidney Int* 2005;67:659-67. doi: 10.1111/j.1523-1755.2005.67122.x pmid: 15673314
- 48 Johnston CI, Ryan NM, Page CB, et al. The Australian Snakebite Project, 2005-2015 (ASP-20). *Med J Aust* 2017;207:119-25. doi: 10.5694/mja17.00094 pmid: 28764620
- 49 Isbister GK, O'Leary MA, Elliott M, Brown SGA. Tiger snake (Notechis spp.) envenoming: Australian Snakebite Project (ASP-13). *Med J Aust* 2012;197:173-7. doi: 10.5694/mja11.11300 pmid: 22860796
- 50 Sitprija V. Snakebite nephropathy. *Nephrology (Carlton)* 2006;11:442-8. doi: 10.1111/j.1440-1797.2006.00599.x pmid: 17014559
- 51 Kularatne SA. Epidemiology and clinical picture of the Russell's viper (Daboia russelii russelii) bites in Anuradhapura, Sri Lanka: a prospective study of 336 patients. *Southeast Asian J Trop Med Public Health* 2003;34:855-62. pmid: 15115100
- 52 Kanjanabuth T, Sitprija V. Snakebite nephrotoxicity in Asia. *Semin Nephrol* 2008;28:363-72. doi: 10.1016/j.semnephrol.2008.04.005 pmid: 18620959
- 53 Hung D-Z, Wu M-L, Deng J-F, Lin-Shiau S-Y. Russell's viper snakebite in Taiwan: differences from other Asian countries. *Toxicon* 2002;40:1291-8. doi: 10.1016/S0041-0101(02)00137-X pmid: 12220714
- 54 Garfin SR, Castiliona RR, Mubarak SJ, Hargens AR, Russell FE, Akeson WH. Rattlesnake bites and surgical decompression: results using a laboratory model. *Toxicon* 1984;22:177-82. doi: 10.1016/0041-0101(84)90018-7 pmid: 6729838
- 55 Gold BS, Barish RA, Dart RC, Silverman RP, Bochicchio GV. Resolution of compartment syndrome after rattlesnake envenomation utilizing non-invasive measures. *J Emerg Med* 2003;24:285-8. doi: 10.1016/S0736-4679(02)00762-X pmid: 12676299
- 56 Kularatne SA. Common krait (Bungarus caeruleus) bite in Anuradhapura, Sri Lanka: a prospective clinical study, 1996-98. *Postgrad Med J* 2002;78:276-80. doi: 10.1136/pmj.78.919.276 pmid: 12151569
- 57 Saini RK, Singh S, Sharma S, Rampal V, Manhas AS, Gupta VK. Snake bite poisoning presenting as early morning neuroparalytic syndrome in jhuggi dwellers. *J Assoc Physicians India* 1986;34:415-7. pmid: 3771478
- 58 Bawaskar HS, Bawaskar PS. Snake bite poisoning. *J Mahatma Gandhi Inst Med Sci*. 2015;20:5-14doi: 10.4103/0971-9903.151717.
- 59 Gutiérrez JM. Current challenges for confronting the public health problem of snakebite envenoming in Central America. *J Venom Anim Toxins Incl Trop Dis* 2014;20:7. doi: 10.1186/1678-9199-20-7 pmid: 24602234
- 60 Sharma SK, Bovier P, Jha N, Alirol E, Loutan L, Chappuis F. Effectiveness of rapid transport of victims and community health education on snake bite fatalities in rural Nepal. *Am J Trop Med Hyg* 2013;89:145-50. doi: 10.4269/ajtmh.12-0750 pmid: 23568287
- 61 Mallik S, Singh SR, Sahoo S, Mohanty MK. Ornament induced complications in snake bites: Revisiting the "Do it RIGHT" approach. *J Family Med Prim Care* 2016;5:474-6. doi: 10.4103/2249-4863.192351 pmid: 27843867
- 62 Anker RL, Straffon WG, Loiselle DS, Anker KM. Retarding the uptake of "mock venom" in humans: comparison of three first-aid treatments. *Med J Aust* 1982;1:212-4. doi: 10.5694/j.1326-5377.1982.tb132272.x pmid: 7087836
- 63 Avau B, Borra V, Vandekerckhove P, De Buck E. The treatment of snake bites in a first aid setting: a systematic review. *PLoS Negl Trop Dis* 2016;10:e0005079. doi: 10.1371/journal.pntd.0005079 pmid: 27749906
- 64 Sutherland SK, Coulter AR, Harris RD. Rationalisation of first-aid measures for elapid snakebite. *Lancet* 1979;1:183-6. doi: 10.1016/S0140-6736(79)90580-4 pmid: 84206
- 65 Helden DFV, Dosen PJ, O'Leary MA, Isbister GK. Two pathways for venom toxin entry consequent to injection of an Australian elapid snake venom. *Sci Rep* 2019;9:8595. doi: 10.1038/s41598-019-45022-4 pmid: 31197231
- 66 Seifert SA, White J, Currie BJ. Commentary: pressure bandaging for North American snake bite? *NoJ Med Toxicol* 2011;7:324-6. doi: 10.1007/s13181-011-0188-9 pmid: 22065371

- 67 Bush SP, Green SM, Laack TA, Hayes WK, Cardwell MD, Tanen DA. Pressure immobilization delays mortality and increases intracompartmental pressure after artificial intramuscular rattlesnake envenomation in a porcine model. *Ann Emerg Med* 2004;44:599-604. doi: 10.1016/j.annemergmed.2004.06.007 pmid: 15573035
- 68 Isbister GK, Brown SG, Page CB, McCoubrie DL, Greene SL, Buckley NA. Snakebite in Australia: a practical approach to diagnosis and treatment. *Med J Aust* 2013;199:763-8. doi: 10.5694/mja12.11172 pmid: 24329653
- 69 Parker-Cote J, Meggs WJ. First aid and pre-hospital management of venomous snakebites. *Trop Med Infect Dis* 2018;3:E45. doi: 10.3390/tropicalmed3020045 pmid: 30274441
- 70 Tun-Pe Aye-Aye-Myint Khin-Ei-Han Thi-Ha Tin-Nu-Swe . Local compression pads as a first-aid measure for victims of bites by Russell's viper (*Daboia russelii siamensis*) in Myanmar. *Trans R Soc Trop Med Hyg* 1995;89:293-5. doi: 10.1016/0035-9203(95)90547-2 pmid: 7660439
- 71 Abubakar SB, Habib AG, Mathew J. Amputation and disability following snakebite in Nigeria. *Trop Doct* 2010;40:114-6. doi: 10.1258/td.2009.090266 pmid: 20305111
- 72 Michael GC, Thacher TD, Shehu MIL. The effect of pre-hospital care for venomous snake bite on outcome in Nigeria. *Trans R Soc Trop Med Hyg* 2011;105:95-101. doi: 10.1016/j.trstmh.2010.09.005 pmid: 21035155
- 73 Iliyasu G, Tihamiyu AB, Daiyab FM, Tambuwal SH, Habib ZG, Habib AG. Effect of distance and delay in access to care on outcome of snakebite in rural north-eastern Nigeria. *Rural Remote Health* 2015;15:3496. doi: 10.22605/RRH3496 pmid: 26590373
- 74 George M. The role of basic laboratory services in strengthening primary health centres. *Indian J Med Ethics* 2011;8:161-3. doi: 10.20529/IJME.2011.064 pmid: 22106643
- 75 Means R, Cabrera J, Moreno X, Amin R. Remote South American snakebite with extensive myonecrosis. *Clin Pract Cases Emerg Med* 2017;1:47-9. doi: 10.5811/cpcem.2016.11.31220 pmid: 29849429
- 76 Jain R, Rao B. Role of laboratory services in primary health center (PHC) outpatient department performance: an Indian case study. *Prim Health Care Res Dev* 2019;20:e112. doi: 10.1017/S1463423619000537 pmid: 32800012
- 77 Lalloo DG, Trevett AJ, Korinhona A, et al. Snake bites by the Papuan taipan (*Oxyuranus scutellatus canni*): paralysis, hemostatic and electrocardiographic abnormalities, and effects of antivenom. *Am J Trop Med Hyg* 1995;52:525-31. doi: 10.4269/ajtmh.1995.52.525 pmid: 7611559
- 78 Bucarechi F, Capitani EMD, Vieira RJ, et al. Coral snake bites (*Micrurus* spp.) in Brazil: a review of literature reports. *Clin Toxicol (Phila)* 2016;54:222-34. doi: 10.3109/15563650.2015.1135337 pmid: 26808120
- 79 Amaral CF, Campolina D, Dias MB, Bueno CM, Rezende NA. Tourniquet ineffectiveness to reduce the severity of envenoming after *Crotalus durissus* snake bite in Belo Horizonte, Minas Gerais, Brazil. *Toxicol* 1998;36:805-8. doi: 10.1016/S0041-0101(97)00132-3 pmid: 9655642
- 80 Habib AG. Tetanus complicating snakebite in northern Nigeria: clinical presentation and public health implications. *Acta Trop* 2003;85:87-91. doi: 10.1016/S0001-706X(02)00234-6 pmid: 12505187
- 81 Reid HA. Sea-snake bites. *BMJ* 1956;2:73-8. doi: 10.1136/bmj.2.4984.73 pmid: 13329387
- 82 Ariaratnam CA, Sheriff MHR, Arambepola C, Theakston RDG, Warrell DA. Syndromic approach to treatment of snake bite in Sri Lanka based on results of a prospective national hospital-based survey of patients envenomed by identified snakes. *Am J Trop Med Hyg* 2009;81:725-31. doi: 10.4269/ajtmh.2009.09-0225 pmid: 19815895
- 83 Harris JB, Faiz MA, Rahman MR, et al. Snake bite in Chittagong Division, Bangladesh: a study of bitten patients who developed no signs of systemic envenoming. *Trans R Soc Trop Med Hyg* 2010;104:320-7. doi: 10.1016/j.trstmh.2009.12.006 pmid: 20096910
- 84 Blaylock RS. The identification and syndromic management of snakebite in South Africa. *S Afr Fam Pract* 2005;47:48-53. doi: 10.1080/20786204.2005.10873288
- 85 Theakston RDG, Laing GD. Diagnosis of snakebite and the importance of immunological tests in venom research. *Toxins (Basel)* 2014;6:1667-95. doi: 10.3390/toxins6051667 pmid: 24859244
- 86 Warrell DA, Davidson NMCD, Greenwood BM, et al. Poisoning by bites of the saw-scaled or carpet viper (*Echis carinatus*) in Nigeria. *Q J Med* 1977;46:33-62. pmid: 866568
- 87 Sano-Martins IS, Fan HW, Castro SC, et al. Butantan Institute Antivenom Study Group. Reliability of the simple 20 minute whole blood clotting test (WBCT20) as an indicator of low plasma fibrinogen concentration in patients envenomed by Bothrops snakes. *Toxicol* 1994;32:1045-50. doi: 10.1016/0041-0101(94)90388-3 pmid: 7801340
- 88 Isbister GK, Maduwage K, Shahmy S, et al. Diagnostic 20-min whole blood clotting test in Russell's viper envenoming delays antivenom administration. *QJM* 2013;106:925-32. doi: 10.1093/qjmed/hct102 pmid: 23674721
- 89 Wedasingha S, Isbister G, Silva A. Bedside coagulation tests in diagnosing venom-induced consumption coagulopathy in snakebite. *Toxins (Basel)* 2020;12:E583. doi: 10.3390/toxins12090583 pmid: 32927702
- 90 Lamb T, Abouyannis M, de Oliveira SS, et al. The 20-minute whole blood clotting test (20WBCT) for snakebite coagulopathy-A systematic review and meta-analysis of diagnostic test accuracy. *PLoS Negl Trop Dis* 2021;15:e0009657. doi: 10.1371/journal.pntd.0009657 pmid: 34375338
- 91 Naik BN, Bhalla A, Sharma N, et al. Pituitary dysfunction in survivors of Russell's viper snake bite envenomation: A prospective study. *Neurol India* 2018;66:1351-8. doi: 10.4103/0028-3886.241378 pmid: 30233002
- 92 Watt G, Padre L, Tuazon L, Theakston RDG, Laughlin L. Bites by the Philippine cobra (*Naja naja philippinensis*): prominent neurotoxicity with minimal local signs. *Am J Trop Med Hyg* 1988;39:306-11. doi: 10.4269/ajtmh.1988.39.306 pmid: 3177741
- 93 World Health Organization. WHO guidelines for the production, control and regulation of snake antivenom immunoglobulins. *WHO Tech Rep Ser* 2018. https://www.who.int/bloodproducts/Antivenom/GLrevWHO_TRS_1004_web_Annex_5.pdf.
- 94 Alfred S, Bates D, White J, et al. Acute kidney injury following Eastern Russell's viper (*Daboia siamensis*) snakebite in Myanmar. *Kidney Int Rep* 2019;4:1337-41. doi: 10.1016/j.ekir.2019.05.017 pmid: 31517153
- 95 Abubakar SB, Abubakar IS, Habib AG, et al. Nigeria-UK EchiTab Study Group. Pre-clinical and preliminary dose-finding and safety studies to identify candidate antivenoms for treatment of envenoming by saw-scaled or carpet vipers (*Echis ocellatus*) in northern Nigeria. *Toxicol* 2010;55:719-23. doi: 10.1016/j.toxicol.2009.10.024 pmid: 19874841
- 96 Warrell DA, Looareesuwan S, Theakston RD, et al. Randomized comparative trial of three monospecific antivenoms for bites by the Malayan pit viper (*Calloselasma rhodostoma*) in southern Thailand: clinical and laboratory correlations. *Am J Trop Med Hyg* 1986;35:1235-47. doi: 10.4269/ajtmh.1986.35.1235 pmid: 3538922
- 97 Cardoso JL, Fan HW, França FO, et al. Randomized comparative trial of three antivenoms in the treatment of envenoming by lance-headed vipers (*Bothrops jararaca*) in São Paulo, Brazil. *Q J Med* 1993;86:315-25. pmid: 8327649
- 98 Smalligan R, Cole J, Brito N, et al. Crotaline snake bite in the Ecuadorian Amazon: randomised double blind comparative trial of three South American polyspecific antivenoms. *BMJ* 2004;329:1129. doi: 10.1136/bmj.329.7475.1129 pmid: 15539665
- 99 Isbister GK, Duffull SB, Brown SGAASP Investigators. Failure of antivenom to improve recovery in Australian snakebite coagulopathy. *QJM* 2009;102:563-8. doi: 10.1093/qjmed/hcp081 pmid: 19570990
- 100 Tanos PP, Isbister GK, Lalloo DG, Kirkpatrick CMJ, Duffull SB. A model for venom-induced consumptive coagulopathy in snake bite. *Toxicol* 2008;52:769-80. doi: 10.1016/j.toxicol.2008.08.013 pmid: 18831981
- 101 Gulati A, Isbister GK, Duffull SB. Effect of Australian elapid venoms on blood coagulation: Australian Snakebite Project (ASP-17). *Toxicol* 2013;61:94-104. doi: 10.1016/j.toxicol.2012.11.001 pmid: 23151381
- 102 Watson JA, Lamb T, Holmes J, et al. A Bayesian phase 2 model based adaptive design to optimise antivenom dosing: Application to a dose-finding trial for a novel Russell's viper antivenom in Myanmar. *PLoS Negl Trop Dis* 2020;14:e0008109. doi: 10.1371/journal.pntd.0008109 pmid: 33196672
- 103 Calvete JJ, Arias AS, Rodríguez Y, et al. Preclinical evaluation of three polyspecific antivenoms against the venom of *Echis ocellatus*: Neutralization of toxic activities and antivenoms. *Toxicol* 2016;119:280-8. doi: 10.1016/j.toxicol.2016.06.022 pmid: 27377229
- 104 Harrison RA, Oluoch GO, Ainsworth S, et al. Preclinical antivenom-efficacy testing reveals potentially disturbing deficiencies of snakebite treatment capability in East Africa. *PLoS Negl Trop Dis* 2017;11:e0005969. doi: 10.1371/journal.pntd.0005969 pmid: 29045429
- 105 Silva A, Hodgson WC, Isbister GK. Antivenom for neuromuscular paralysis resulting from snake envenoming. *Toxins (Basel)* 2017;9:E143. doi: 10.3390/toxins9040143 pmid: 28422078
- 106 Gutiérrez JM, León G, Rojas G, Lomonte B, Rucavado A, Chaves F. Neutralization of local tissue damage induced by *Bothrops asper* (terciopelo) snake venom. *Toxicol* 1998;36:1529-38. doi: 10.1016/S0041-0101(98)00145-7 pmid: 9792169
- 107 Darracq MA, Cantrell FL, Klauk B, Thornton SL. A chance to cut is not always a chance to cure-fasciotomy in the treatment of rattlesnake envenomation: A retrospective poison center study. *Toxicol* 2015;101:23-6. doi: 10.1016/j.toxicol.2015.04.014 pmid: 25935457
- 108 de Silva HA, Ryan NM, de Silva HJ. Adverse reactions to snake antivenom, and their prevention and treatment. *Br J Clin Pharmacol* 2016;81:446-52. doi: 10.1111/bcp.12739 pmid: 26256124
- 109 Stone SF, Isbister GK, Shahmy S, et al. Immune response to snake envenoming and treatment with antivenom: complement activation, cytokine production and mast cell degranulation. *PLoS Negl Trop Dis* 2013;7:e2326. doi: 10.1371/journal.pntd.0002326 pmid: 23936562
- 110 Premawardhana AP, de Silva CE, Fonseka MM, Gunatillake SB, de Silva HJ. Low dose subcutaneous adrenaline to prevent acute adverse reactions to antivenom serum in people bitten by snakes: randomised, placebo controlled trial. *BMJ* 1999;318:1041-3. doi: 10.1136/bmj.318.7190.1041 pmid: 10205101
- 111 León G, Herrera M, Segura Á, Villalta M, Vargas M, Gutiérrez JM. Pathogenic mechanisms underlying adverse reactions induced by intravenous administration of snake antivenoms. *Toxicol* 2013;76:63-76. doi: 10.1016/j.toxicol.2013.09.010 pmid: 24055551
- 112 Sharma SK, Alirol E, Ghimire A, et al. Acute severe anaphylaxis in Nepali patients with neurotoxic snakebite envenoming treated with the VINS polyvalent antivenom. *J Trop Med* 2019;2019:2689171. doi: 10.1155/2019/2689171 pmid: 31205473
- 113 Dart RC, McNally J. Efficacy, safety, and use of snake antivenoms in the United States. *Ann Emerg Med* 2001;37:181-8. doi: 10.1067/mem.2001.113372 pmid: 11174237
- 114 Ramanayake RPJC, Ranasingha S, Lakmini S. Management of emergencies in general practice: role of general practitioners. *J Family Med Prim Care* 2014;3:305-8. doi: 10.4103/2249-4863.148089 pmid: 25657933
- 115 Jayawardana S, Gnanathanan A, Arambepola C, Chang T. Chronic musculoskeletal disabilities following snake envenoming in Sri Lanka: A population-based study. *PLoS Negl Trop Dis* 2016;10:e0005103. doi: 10.1371/journal.pntd.0005103 pmid: 27814368
- 116 Herath HMNJ, Wazil AWM, Abeysekera DTDJ, et al. Chronic kidney disease in snake envenomed patients with acute kidney injury in Sri Lanka: a descriptive study. *Postgrad Med J* 2012;88:138-42. doi: 10.1136/postgradmedj-2011-130225 pmid: 22282736

- 117 Golay V, Roychowdhary A, Pandey R, Singh A, Pasari A, Abraham A. Acute interstitial nephritis in patients with viperine snake bite: single center experience of a rare presentation. *Saudi J Kidney Dis Transpl* 2012;23:1262-7. pmid: 23168862
- 118 Waikhom R, Sircar D, Patil K, Bennikal M, Gupta SD, Pandey R. Long-term renal outcome of snake bite and acute kidney injury: a single-center experience. *Ren Fail* 2012;34:271-4. doi: 10.3109/0886022X.2011.647297 pmid: 22260154
- 119 Pulimaddi R, Parveda AR, Brahmanpally B, Kalakanda PM, Ramakrishna K, Chinnapaka VRD. Incidence & prognosis of acute kidney injury in individuals of snakebite in a tertiary care hospital in India. *Indian J Med Res* 2017;146:754-8. doi: 10.4103/ijmr.IJMR_1581_16 pmid: 29664034
- 120 Priyamvada PS, Jaswanth C, Zachariah B, Haridasan S, Parameswaran S, Swaminathan RP. Prognosis and long-term outcomes of acute kidney injury due to snake envenomation. *Clin Kidney J* 2019;13:564-70. doi: 10.1093/ckj/sfz055 pmid: 32905257
- 121 Antonypillai CN, Wass JA, Warrell DA, Rajaratnam HN. Hypopituitarism following envenoming by Russell's vipers (*Daboia siamensis* and *D. russelii*) resembling Sheehan's syndrome: first case report from Sri Lanka, a review of the literature and recommendations for endocrine management. *QJM* 2011;104:97-108. doi: 10.1093/qjmed/hcq214 pmid: 2115460
- 122 Srinivasan KG, Srividya S, Usha Nandhini KP, Ramprabanth S. Chronic pituitary failure resembling Sheehan's syndrome following a bite of Russell's viper. A case report. *Neuroradiol J* 2010;23:38-41. doi: 10.1177/197140091002300106 pmid: 24148331
- 123 Shivaprasad C, Aiswarya Y, Sridevi A, et al. Delayed hypopituitarism following Russell's viper envenomation: a case series and literature review. *Pituitary* 2019;22:4-12. doi: 10.1007/s11102-018-0915-1 pmid: 30317419
- 124 Williams DJ, Habib AG, Warrell DA. Clinical studies of the effectiveness and safety of antivenoms. *Toxicon* 2018;150:1-10. doi: 10.1016/j.toxicon.2018.05.001 pmid: 29746978
- 125 Ascoët S, De Waard M. Diagnostic and therapeutic value of aptamers in envenomation cases. *Int J Mol Sci* 2020;21:E3565. doi: 10.3390/ijms21103565 pmid: 32443562
- 126 Williams HF, Layfield HJ, Vallance T, et al. The urgent need to develop novel strategies for the diagnosis and treatment of snakebites. *Toxins (Basel)* 2019;11:E363. doi: 10.3390/toxins11060363 pmid: 31226842